

# Robinson Veterinary Services

3285 London Line Wyoming, ON N0N1T0

Phone: 519-542-9588

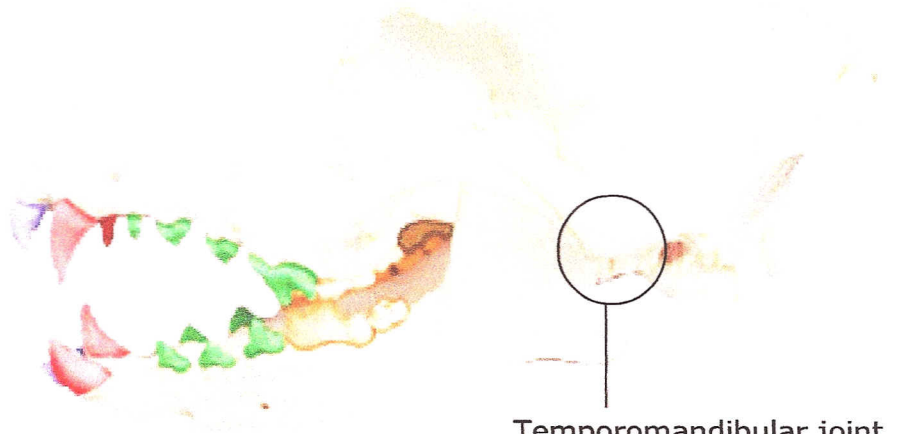
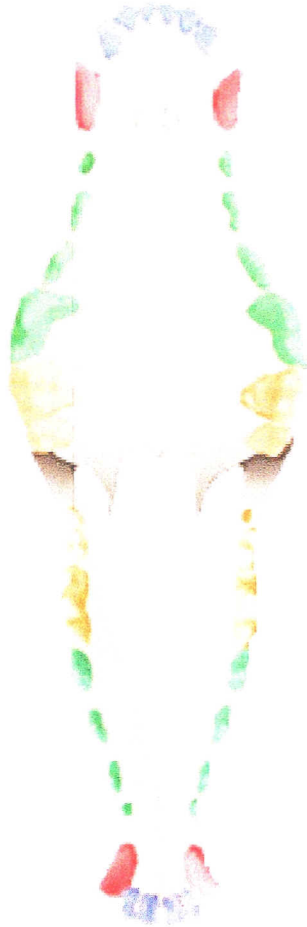Fax: 519-542-8789

Web: [www.robinsonvet.com](http://www.robinsonvet.com)

Dentition - Dog: Skull of dog showing adult dentition.



42 Teeth: 20 Upper Teeth + 22 Lower Teeth



Temporomandibular joint  
(allows mouth to  
open and close)

Used Under License  
Copyright© Lifelearn Inc.

The adult dog has a total of 42 teeth. The structure and shape of the teeth are adapted to the 'omnivorous diet' of the dog, that includes prey animals and vegetation. The large, sharp canine teeth are capable of penetrating deep into tissues, allowing the dog to hold tightly onto its food. The incisor teeth assist in grasping and holding the food item in the mouth. The sharp premolars tear the food into smaller pieces, while the flattened surfaces of the molars also crush and grind the food. The last upper premolar teeth and the first lower molar teeth are specialized teeth in carnivores and are also called the carnassial teeth. The spaces between the canines, premolars, and molars allow the upper and lower jaw to mesh together for efficient holding and tearing of the food.